

Dentale Präparationssimulatoren - die Ausbildung der Zukunft?

Rüdiger Lemke

Poliklinik für Zahnerhaltung und Präventive Zahnheilkunde
und
VOXEL-MAN Arbeitsgruppe

Universitätsklinikum Hamburg-Eppendorf (UKE)

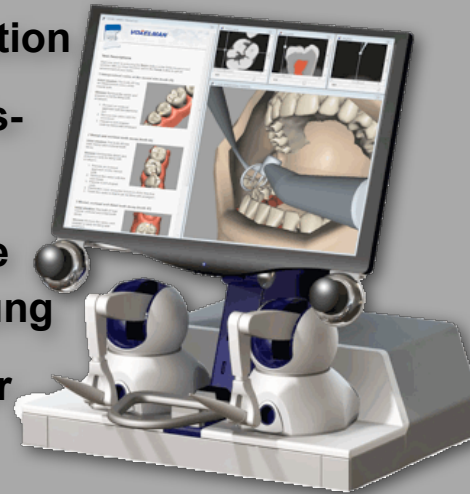


Phantomkurse der Unikliniken

- Modelle mit Kunststoffzähnen
oder extrahierte Zähne
- Kosten Vollinstrumentierung
(Studiengebühren)
- Subjektive
Qualitätsbeurteilung

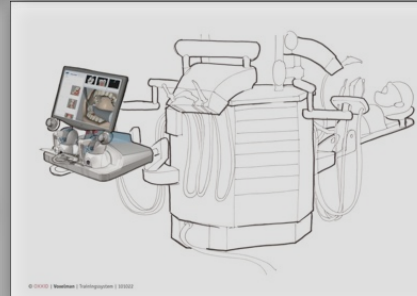


- **Ergebnisse der Lehrevaluation**
- **Studienplan und Kapazitätsvorgaben**
- **Qualitative und quantitative Verbesserung der Ausbildung**
- **Innovative Veränderung der Lehrmethoden**
- **Praktisches Selbststudium**



Anforderungen

- Realitätsnahe Haptik
- Realitätsnaher Zahnstatus
- Individuelle Anpassung der Anforderungskriterien
- Pathologische Strukturen
- Rekapitulierbares Training
- Integrierte Beurteilung

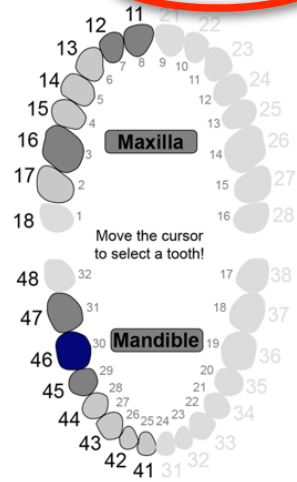




VOXEL-MAN

Getting Started

Dental



Tooth 46 selected.

Free Preparation

Specific Preparation

Choose Preparation Material:

Amalgam

Composite

Gold

Choose Cavity Type:

mesial

mesial-occlusal

mesial-occlusal-distal

palatal-distal

palatal-mesial

Carious Lesions:

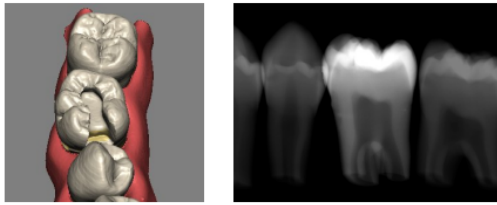
included

not included

Start as:

Training

Examination



Evaluate

Preparation of mesial and occlusal tooth decay (tooth 46)

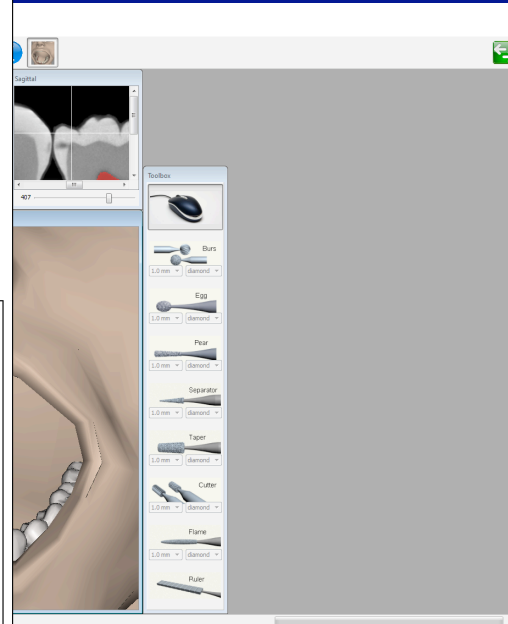
Complete the given task. After you have finished, press the EVALUATE button to get an assessment of your skills.

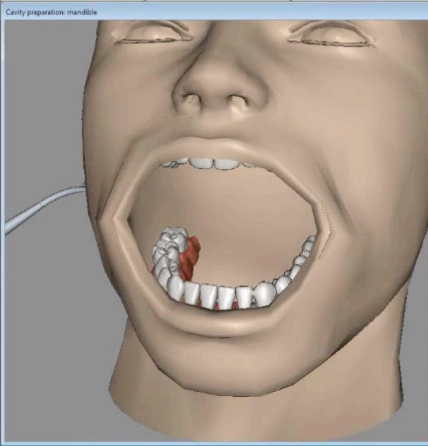
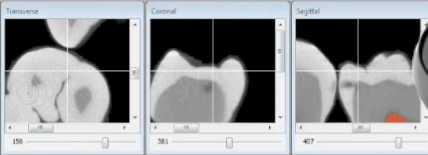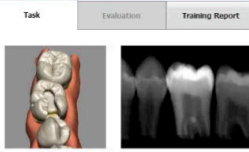Situation: The tooth 46 has both mesial and occlusal tooth decay.

Mission: Remove the caries and prepare a cavity for filling with amalgam.

1. Prepare an occlusal approach on the mesial side.
2. Remove the caries with the rose-head.
3. Prepare a slot shaped cavity.
4. Extend this cavity along the fissure in distal direction.
5. Finish the cavity so that it can be filled with amalgam.

Author: Ruediger Lemke, DDS, Supervisor of Dental Phantom Course,
Department of Restorative and Preventive Dentistry, University Medical
Center Hamburg-Eppendorf, Germany





Preparation of mesial and occlusal tooth decay (tooth 46)

Complete the given task. After you have finished, press the EVALUATE button to get an assessment of your skills.

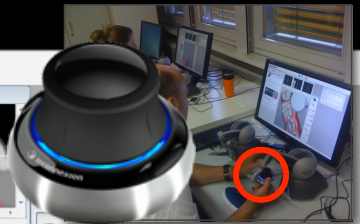
Situation: The tooth 46 has both mesial and occlusal tooth decay.

Mission: Remove the caries and prepare a cavity for filling with amalgam.

1. Prepare an occlusal approach on the mesial side.
2. Remove the caries with the rose-head.
3. Prepare a slot shaped cavity.
4. Extend this cavity along the fissure in distal direction.
5. Finish the cavity so that it can be filled with amalgam.

Author: Ruediger Lemke, DDS, Supervisor of Dental Phantom Course, Department of Restorative and Preventive Dentistry, University Medical Center Hamburg-Eppendorf, Germany

- Burs
- Egg
- Pear
- Separator
- Taper
- Cuttr
- Flame
- Piler





VOXEL-MAN

Session Manager

Task Evaluation Training Report

Evaluate

Preparation of mesial and occlusal tooth decay (tooth 45)

Complete the given task. After you have finished, press the EVALUATE button to get an assessment of your skills.

Situation: The tooth 45 has both mesial and occlusal tooth decay.

Mission: Remove the caries and prepare a cavity for filling with amalgam.

1. Prepare an occlusal approach on the mesial side.
2. Remove the caries with the rose-head.
3. Prepare a slot shaped cavity.
4. Extend this cavity along the fissure in distal direction.
5. Finish the cavity so that it can be filled with amalgam.

Author: Ruediger Lemke, DDS, Supervisor of Dental Phantom Course, Department of Restorative and Preventive Dentistry, University Medical Center Hamburg-Eppendorf, Germany

Transverse Sagittal

156

Cavity preparation

Toolbox

- Burs
- Egg
- Pear
- Separator
- Tap
- Cutter
- Flame
- Duler

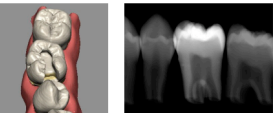


VOXEL-MAN



Section Manager

Task Evaluation Training Report



Evaluate

Preparation of mesial and occlusal tooth decay (tooth 46)

Complete the given task. After you have finished, press the EVALUATE button to get an assessment of your skills.

Situation: The tooth 46 has both mesial and occlusal tooth decay.

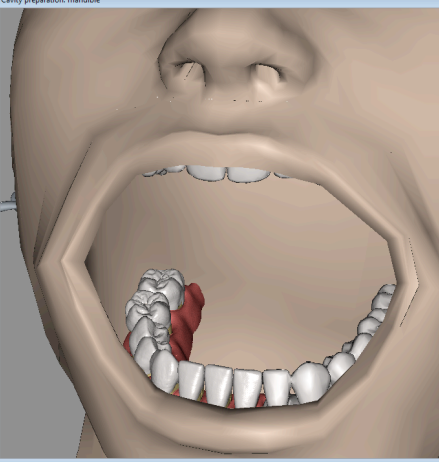
Mission: Remove the caries and prepare a cavity for filling with amalgam.

1. Prepare an occlusal approach on the mesial side.
2. Remove the caries with the rose-head.
3. Prepare a slot shaped cavity.
4. Extend this cavity along the fissure in distal direction.
5. Finish the cavity so that it can be filled with amalgam.

Author: Ruediger Lemke, DDS, Supervisor of Dental Phantom Course, Department of Restorative and Preventive Dentistry, University Medical Center Hamburg-Eppendorf, Germany

Transverse 156 Coronal 381 Sagittal 407

Cavity preparation: mandible

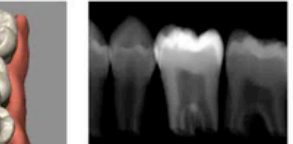


Toolbox

- Burs (1.0 mm diamond)
- Egg (1.0 mm diamond)
- Pear (1.0 mm diamond)
- Separator (1.0 mm diamond)
- Taper (1.0 mm diamond)
- Cutter (1.0 mm diamond)
- Flame (1.0 mm diamond)
- Ruler

3M

Evaluation Training Report



Evaluate

mesial and occlusal tooth decay (tooth 46)

When task is finished, press the EVALUATE button for assessment of your skills.

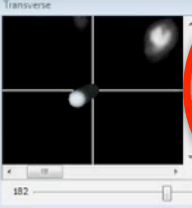
Tooth 46 has both mesial and occlusal tooth decay.

Remove the caries and prepare a cavity for filling with amalgam.


- Use an occlusal approach on the mesial side.
- Remove caries with the rose-head.
- Prepare a slot shaped cavity.
- Prepare a cavity along the fissure in distal direction.
- Prepare a cavity so that it can be filled with amalgam.

Larmer, DDS, Supervisor of Dental Phantom Course, Restorative and Preventive Dentistry, University Medical Eppendorf, Germany

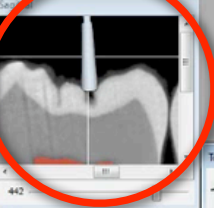
Transverse



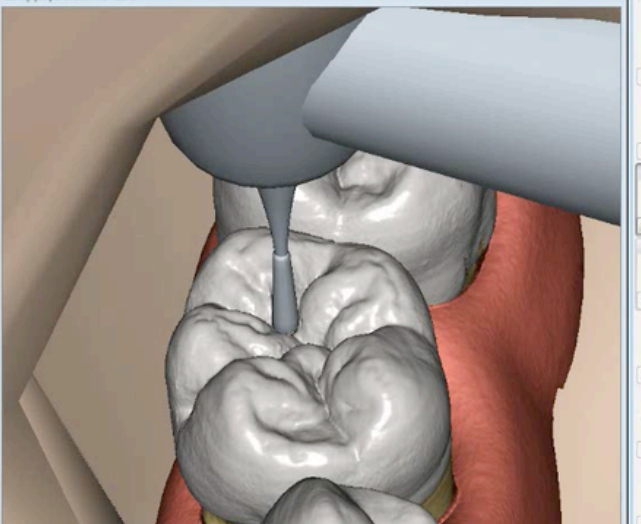
442



442



Cavity preparation: mandible



Toolbox

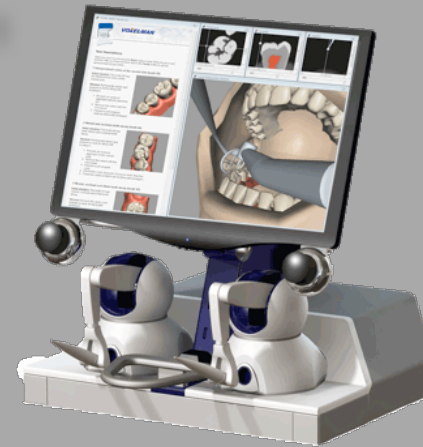- Bur
- 1.0 mm diamond
- Egg
- 1.0 mm diamond
- Pear
- 1.0 mm diamond
- Separ
- 1.0 mm diamond
- Taper
- 1.0 mm diamond
- Cut
- 1.0 mm diamond
- Flame
- 1.0 mm diamond

Pilotstudie

- Wintersemester 2010/2011
- 12 Studierende
- je 25 Arbeitsstunden

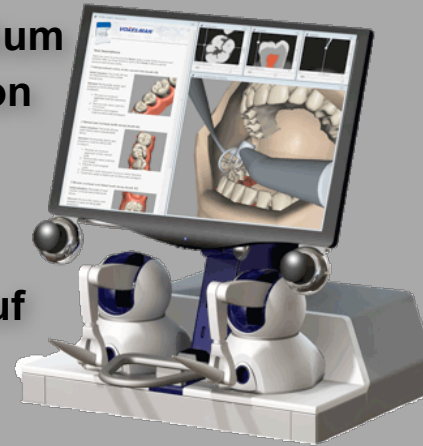
Erste Evaluation

- Sommersemester 2011
- 18 Studierende
- je 25 Arbeitsstunden



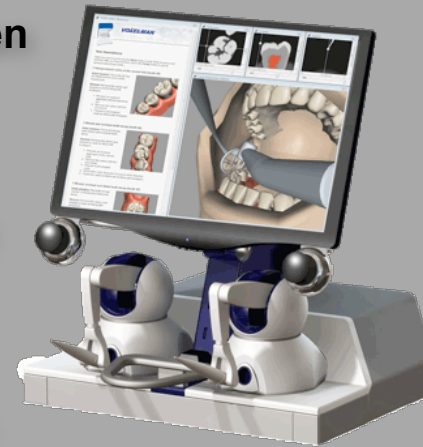Fazit der Studierenden

- **Motivation zum Selbststudium bei realitätsnaher Simulation**
- **Erfolgskontrolle beim Selbststudium**
- **Intensivere Vorbereitung auf die Patientenbehandlung**



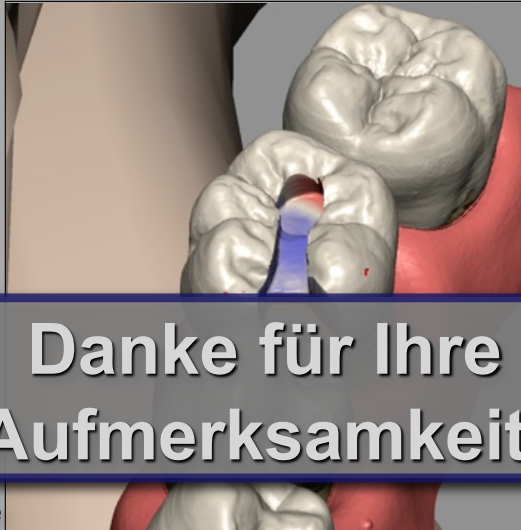Fazit der Lehrenden

- Möglichkeit der qualitativen und quantitativen Verbesserung der Lehre
- Individuellere Ausbildung
- Kapazitätsneutrales Lehrangebot
- Bessere Vorbereitung auf die Patientenbehandlung





Probieren Sie es selbst!



**Danke für Ihre
Aufmerksamkeit!**